ORIGINAL ARTICLE

Correlations of Anatomical Parameters in Dynamic Pelvic CT and Conventional Defecography for Patients with Rectal Prolapse

Norihiro Okamoto

Department of Surgery, Shinshiro Municipal Hospital, Aichi, Japan

(Received for publication on June 5, 2008)
(Revised for publication on August 29, 2008)
(Accepted for publication on September 18, 2008)

Abstract. Purpose: To evaluate the correlations of anatomical parameters between dynamic pelvic CT (D-PCT) and conventional defecography (CD) for patients with rectal prolapse.

Material and Methods: Anatomical parameters in multislice CT scanning of the pelvis performed at rest and during simulated defecation (D-PCT) were studied with those of CD to evaluate the correlations in both methods for 10 patients with rectal prolapse.

Result: The correlation coefficients of the pubococcygeal line and the pubosacral line were r=0.6 and r=0.8 respectively. The length from anal verge to pubococcygeal line and to the pubosacral line showed a good correlation of r=0.7. The length of puborectal muscle showed a good correlation of r=0.8. Anorectal angle was significantly well correlated between two methods (r=0.9, $p<0.05$). The lengths of anococcygeal length and anosacral length showed a good correlation.

Conclusion: The anatomical parameters measured by D-PCT were well correlated with those by CD. D-PCT might be an alternative tool for anatomical evaluation of the anorectal region in patients with rectal prolapse. (Keio J Med 57 (4) : 205−210, December 2008)

Key words: defecography, dynamic pelvic CT, rectal prolapse, defecation disorders, anorectal angle

Introduction

Conventional defecography (CD) has been the most commonly employed diagnostic imaging modality for morphological and physiological evaluation of the anorectal region in patients with functional anorectal diseases. Lateral images of the pelvic region have been used to obtain various anatomical measurements. The pubic bone and the coccyx were often used as indicators in CD.[1−4] However, the anatomy of the coccyx varies from person to person with frequent incomplete visualization of the bone on X-ray images. In the present study, the author employed multislice CT during simulated defecation (D-PCT) to evaluate various anatomical measurements by using the pubococcygeal line and the pubosacral line, which are considered to be morphologically consistent and poorly visualized by plain X-ray. The correlations of morphological or physiological parameters between D-PCT and CD were investigated.

Materials and Methods

Ten patients (6 men, median age 62.8) with rectal prolapse were enrolled in this study. Rectal prolapse was classified as type II in 9 patients and III in 1 patient according to the Tuttle classification.[1] Seven patients were constipated and 1 patient had soiling (Table. 1).

CD: Laxative was administered on the previous day. A glycerin enema was performed prior to the study on the date of the examination, and defecation was completed at least 1 hour. The patient was placed in the left lateral decubitus position prior to the examination. A 100 ml of barium mixed with rice bran was administered through the anus, and the running of the intestinal tract was initially determined. The barium was confirmed to reach the sigmoid colon for adequate filling of the rectum. A portable commode was mounted on the fluorography table, and right lateral images were obtained with the patient at rest in the sitting position. Images were also ob-

Corresponding author: Norihiro Okamoto, MD. 32-1, Kitahata, Shinshiro, Aichi, 441-1387, Japan, Tel: +81-536-22-2171, Fax: +81-536-22-2850, E-mail: norihiro_okamoto@yahoo.co.jp

Table 1 Patient characteristics

Number of patients	10
Gender (male / female)	6/4
Age (year), median (range)	62.8 (32-75)
Bowel habit	
normal	2
constipation	7
diarrhea	0
Soiling	1
Classification (Tuttles)	
Ⅰ	0
Ⅱ	9
Ⅲ	1

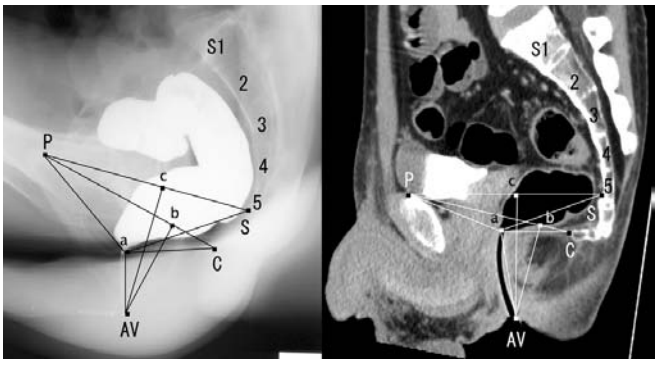

Fig. 1 Points of anatomical measurement
Lateral images of both conventional defecography and dynamic pelvic CT
P : superior margin of the pubic bone
S : inferior margin of the 5th sacral bone
C : tip of coccyx
AV : anal verge

tained during squeezing and straining. Imaging was completed in approximately 20 minutes. Anatomical measurements were performed by using X-ray films.

D-PCT: One day before imaging, a laxative was administered and intestinal lavage was performed. The patient was placed in the prone position on CT scanner. Immediately before imaging, a small catheter (14Fr) was placed in the anus and 300 ml of air was infused to expand the rectum. CT images were acquired by using a multislice CT system with a 16-row detector and 16 data acquisition systems (Aquilion 16 DAS, Toshiba). Helical scanning was performed with a detector collimation of 1 mm, a beam pitch of 0.94 (helical pitch 15), and a table movement speed of 30 mm/sec. The contrast medium, 100 ml of Iopamidol (370 mgI/ml), was injected at a rate of 2.5 ml/sec to enhance contrast with other structures, and scan start was triggered using a function for automatically determining the optimal scan timing (SureStart, Toshiba). Images were obtained during four phases, at rest of plain, arterial, venous, and equivalent phase, at squeeze and strain of equivalent phase. CT images were obtained at rest, and contrast medium was injected in about 40 seconds, at squeeze and strain phases were after this in 1 to 2 minutes. Imaging was completed in approximately 5 minutes. The scan data was reconstructed into 1 mm slice thickness and 0.5 mm overlap. Multiplanar reconstruction (MPR) images of this data set were created on a workstation (ALATOVIEW, Toshiba). Based on the MPR images, anatomical measurements were obtained.

Measurements: Lateral images of both D-PCT and CD were used to evaluate anatomical measurements. The pubococcygeal line (Fig 1, the superior margin of the pubic bone to the tip of coccyx) and the pubosacral line (Fig 1, the superior margin of the pubic bone to the inferior margin of the 5th sacral bone) were used for measurements. The distance between the superior margin of the pubic bone and the upper margin of the anal canal was measured, and this measurement was defined to represent the length of the puborectal muscle. In addition, the distances from the inferior margin of the 5th sacral vertebra to the upper margin of the anal canal and from the tip of the coccyx to the upper margin of the anal canal were measured. Measurements were obtained during three phases: at rest, at squeeze and at strain (Fig. 1).

The correlation values were calculated as Pearson correlation coefficients (r), and statistical analysis was performed using the Fisher (z) conversion (p) value. A p value less than 0.05 was considered as significant.

Results

The mean measurement and standard deviation (SD) values for the pubococcygeal line (P-C) at rest, during squeezing, and during straining obtained by CD were 168.4±10.8 mm (160-196 mm), 166.3±11.2 mm (158-190 mm), and 177.8±11.9 mm (167-201 mm), respectively. The corresponding measurement values obtained by D-PCT were 114.9±7.4 mm (108-149 mm), 112.6±8.2 mm (106-138 mm), and 118.8±7.8 mm (107-141 mm), respectively. A positive correlation was observed in all phases: at rest (r=0.6, p=0.10), during squeezing (r=0.6, p=0.11), and during straining (r=0.6, p=0.10). The mean measurement and SD values for the pubosacral line (P-S) at rest, during squeezing, and during straining obtained by CD were 176.5±10.1 mm (165-191 mm), 176.5±11.6 mm (163-190 mm), and 177.8±12.1 mm (164-189 mm), respectively. Those obtained by D-PCT were 129.6±9.1 mm (122-147 mm), 129.5±8.1 mm (123-146 mm), and 130.0±8.4 mm (125-146 mm), respectively. A strong positive correlation was observed in all phases: at rest (r=0.8, p=0.02), during squeezing (r=0.7, p=0.03), and during straining (r =

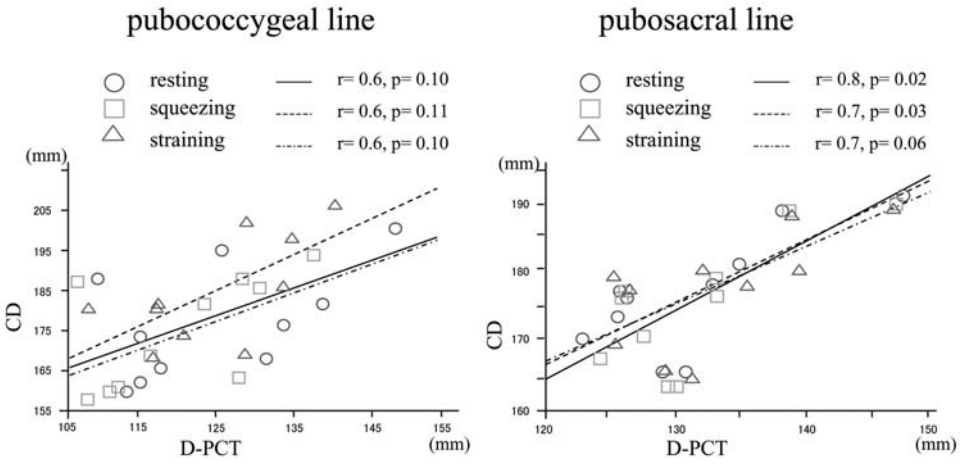

Fig. 2 Pubococcygeal and pubosacral length

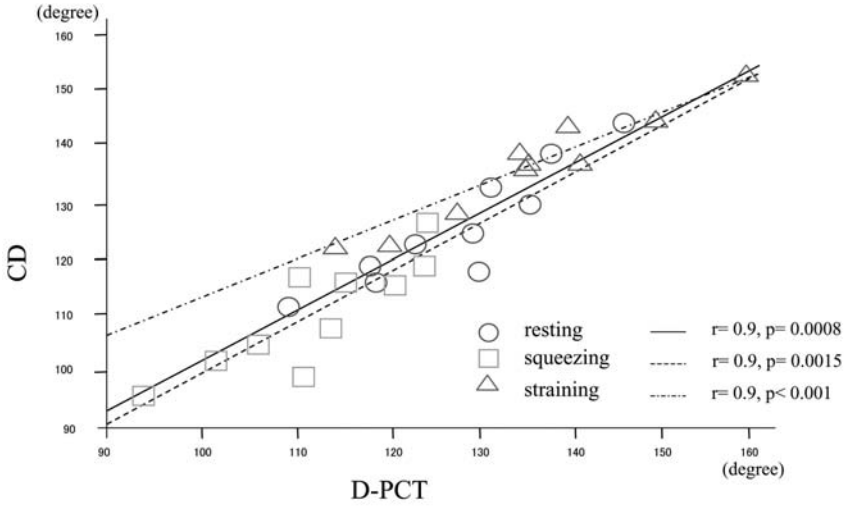

Fig. 3 Anorectal angle

0.7, p=0.06) (Fig. 2).

The mean measurement and SD values for the anorectal angle (AV-a-S, AV-a-C) at rest, during squeezing, and during straining obtained by CD were 122.0±8.6º (113-146º), 107.5±9.2º (97-128º), and 139.0±9.1º (123-154º), respectively. Those obtained by D-PCT were 125.8±4.2º (109-145º), 112.2±6.1º (93-124º), and 137.2±5.2º (114-158º), respectively. A statistically significant strong positive correlation was observed in all phases: at rest (r=0.9, p=0.0008), during squeezing (r=0.9, p=0.0015), and during straining (r=0.9, p<0.001) (Fig. 3).

The mean measurement and SD values for length from anal verge relative to the pubococcygeal line (AV-b) at rest, during squeezing, and during straining obtained by CD were 58.6±8.2 mm (30-85 mm), 51.4±7.4 mm (38-70 mm), and 91.2±8.1 mm (32-137 mm), respectively. Those obtained by D-PCT were 29.5±5.1 mm (18-50 mm), 26.9±4.8 mm (15-34 mm), and 53.6±5.7 mm (20-65 mm), respectively. A positive correlation was observed in all phases: at rest (r=0.7, p=0.09), during squeezing (r= 0.4, p=0.31), and during straining (r=0.7, p=0.04). The mean measurement and SD values for length from anal verge relative to the pubosacral line (AV-c) at rest, during squeezing, and during straining obtained by CD were 71.5±9.8 mm (52-80 mm), 63.0±9.6 mm (53-67 mm), and 108.0±10.1 mm (80-135 mm), respectively. Those obtained by D-PCT were 46.7±6.1 mm (35-70 mm), 38.7±7.2 mm (27-52 mm), and 73.0±7.6 mm (40-83 mm), respectively. A positive correlation was

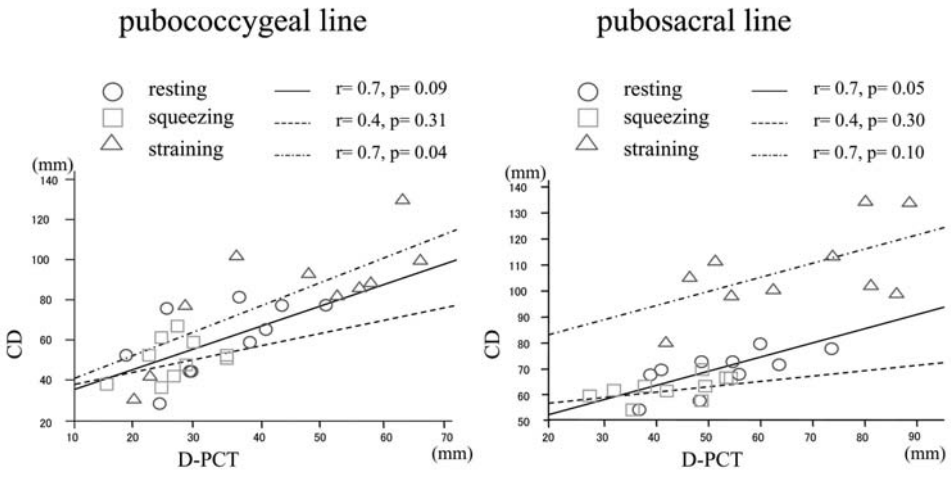

Fig. 4 Length from anal verge to pubococcygeal and pubosacral line

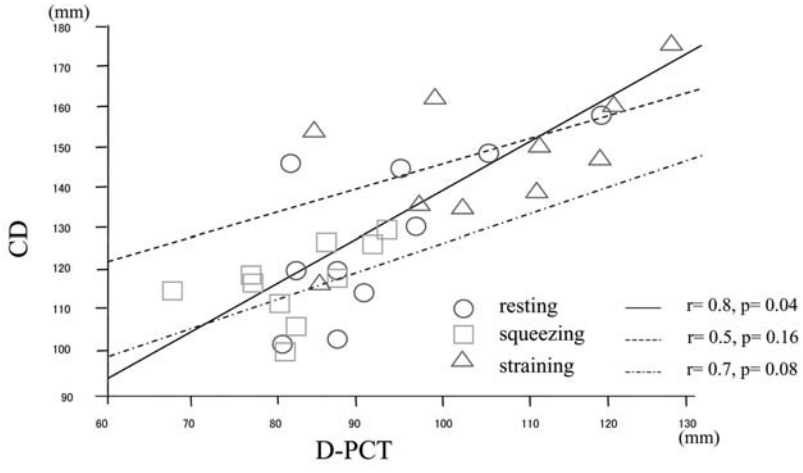

Fig. 5 Puborectal muscle length

observed in all phases: at rest (r=0.7, p=0.05), during squeezing (r=0.4, p=0.30), and during straining (r=0.7, p=0.10) (Fig. 4).

The mean measurement and SD values for the puborectal muscle length (P-C, P-S) at rest, during squeezing, and during straining obtained by CD were 133.1±10.1 mm (102-158 mm), 112.5±9.8 mm (100-130 mm), and 153.0±10.2 mm (116-173 mm), respectively. Those obtained by D-PCT were 87.1±6.2 mm (80-118 mm), 81.3±7.4 mm (67-92 mm), and 109.7±9.1 mm (84-126 mm), respectively. A positive correlation was observed in all the phases: at rest (r=0.8, p=0.04), during squeezing (r=0.5, p=0.16), and during straining (r=0.7, p=0.08) (Fig. 5).

The mean measurement and SD values for anococcygeal length relative to the pubococcygeal line (a-C) at rest, during squeezing, and during straining obtained by CD were 84.3±11.2 mm (67-90 mm), 85.2±10.1 mm (62-117 mm), and 105.2±9.2 mm (86-114 mm), respectively. Those obtained by D-PCT were 46.6±8.7 mm (38-67 mm), 49.8±9.1 mm (38-61 mm), and 58.1±10.1 mm (46-72 mm), respectively. A correlation was observed in all phases: at rest (r=0.5, p=0.07), during squeezing (r= -0.5, p=0.21), and during straining (r=0.4, p=0.31). The mean measurement and SD values for anosacral length relative to the pubosacral line (a-S) at rest, during squeezing, and during straining obtained by CD were 100.4±11.1 mm (97-145 mm), 96.8±10.2 mm (88-140 mm), and 118.2±11.7 mm (111-127 mm), respectively. Those obtained by D-PCT were 70.6±10.1

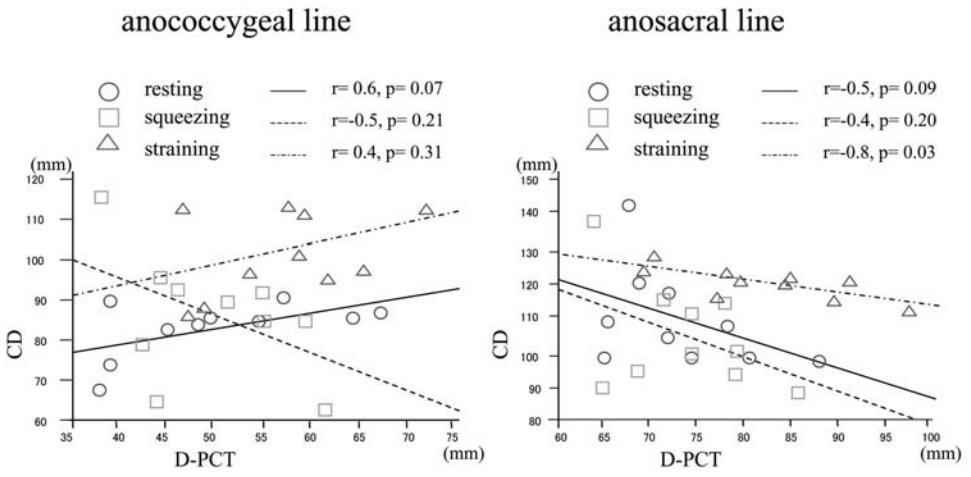

Fig. 6 Anococcygeal and anosacral length

mm (65-88 mm), 49.7±11.2 mm (38-61 mm), and 84.9± 9.7 mm (69-97 mm), respectively. A negative correlation was observed in all phases: at rest (r= -0.5, p=0.09), during squeezing (r= -0.4, p=0.20), and during straining (r= -0.8, p=0.03) (Fig. 6).

Discussion

The current technique of CD, which is widely employed, has its origins in the method reported as cinefluorography by Wallden, Burhenn, and others.[1] Later, in the 1980s, the usefulness of CD for the evaluation of anorectal morphological abnormalities associated with defecation was reported in Europe and the United States.[4,6–10] In recent years, there have been significant advances in MSCT, which permits high-speed helical scanning at a speed of 30 mm/s or more, resulting in substantial reductions in the times required for CT evaluation and examination. The authors therefore employed CT scanning to obtain images during defecation an imaging method referred to as "Dynamic Pelvic CT", and conducted clinical evaluations. Imaging systems such as those employed in the present study allow scanning times to be substantially reduced and also permit pelvis to be evaluated simultaneously. In lateral images obtained by CD, the anatomy and number of bones of the coccyx differ from person to person, and the coccyx is often abnormal due to fracture. Furthermore, due to the limitations of X-ray examinations, visualization of the coccyx is often difficult. Therefore, the author obtained measurements relative to the inferior margin of the 5th sacral vertebra, which has a consistent anatomy and is easy to detect in X-ray examinations. The results showed a correlation between the findings obtained by CD and by D-PCT with regard to the pubococcygeal line, the pubosacral line, the length from anal verge, the anorectal angle, and the puborectal muscle length. However, not all of the actual measurement values showed statistically significant correlations. Generally, the distances obtained by D-PCT are considered to be the true values, which tend to be increased in X-ray examinations. Therefore, the author performed statistical analysis using both corrected and actual measurement values, but the results were the same. The reason that the correlations were not statistically significant was thought to be attributable to patient positioning. CD was performed with the patient in the sitting position, which is the usual position for defecation, while D-PCT was performed with the patient in the prone position. The difference in patient positioning was thought to result in differences related to gravitational effects and the forces applied by the patient during straining and during squeezing. In addition, the intestines were filled with a mixture of rice bran and barium (similar to feces) in CD, but with air in D-PCT, which may have resulted in differences during defecation. The measurement error caused by slight body movement during CD may also have been a factor. As a similar diagnostic method, it would also be possible to perform examination using sagital and coronal images obtained by MRI.[11–13] However, this is not practical in the clinical setting due to a number of problems such as long imaging times, difficulties in patient positioning due to the limited space within the system, and image distortion. The author obtained measurements using both CD and D-PCT and evaluated the correlations between these two diagnostic imaging methods. The results of the present study indicate that D-PCT, although it is not equivalent to CD in terms of clinical acceptance, is capable of providing comparable morphological measurements in patients with rectal prolapse. D-PCT permits not only the

rectum but also pelvic structure to be examined at the same time and is therefore suitable for the evaluation of pathologic changes in all of the intra pelvic organs.[14,15] The anatomical measurements obtained by D-PCT showed correlations with those obtained by CD and are therefore considered to be suitable for morphological evaluation of the anorectal region in patients with rectal prolapse.

References

1. Burhenne HJ: Intestinal evacuation study: A new rentogenologic technique. Radiol Clin 1964; 33:79–84
2. Mellgren A, Bremmer S, Johansson C, Dolk A, Udén R, Ahlbäck SO, Holmström B: Defecography. Results of investigations in 2,816 patients. Dis Colon Rectum 1994; 37:1133–1141
3. Wexner SD, Gilliland R: Setting up a colorectal physiology labolatory. In colon and rectal surgery. 4th ed, Corman M L ed, J.B. Lippincott, Philadelphia, 1998
4. Altringer WE, Saclarides TJ, Dominguez JM, Brubaker LT, Smith CS: Four-contrast defecography: pelvic floor-oscopy. Dis Colon Rectum 1995; 38:695–699
5. Womack NR, Williams NS, Holmfield J HM, Morrison JF, Simpkins KC: New method for the dynamic assessment of anorectal function in costipation. Br J Surg 1985; 72:994–998
6. Lahr CJ, Rothenberger DA, Jensen LL, Goldberg SM: Balloon topography: a simple method of evaluating anal function. Dis Colon Rectum 1986; 29:1–5
7. Jorge JM, Wexner SD, Marchetti F, Rosato GO, Sullivan ML, Jagelman DG: How reliable are currently available methods of measuring the anorectal angle? Dis Colon Rectum 1992 35:332–338
8. Felt-Bersma RJF, Luth WJ, Janssen JJ, Meuwissen SG: Defecography in patients with anorectal disorders. Which findings are clinically relevant? Dis Colon Rectum 1990; 33:277–284
9. Ferrante SL, Perry RE, Schreiman JS, Cheng SC, Frick MP: The reproducibility of measuring the anorectal angle in defecography. Dis Colon Rectum 1991; 34:51–55
10. Hock D, Lombard R, Jehaes C, Markiewicz S, Penders L, Fontaine F, Cusumano G, Nelissen G: Colpocysto-defecography. Dis Colon Rectum 1993; 36:1015–1021
11. Comiter CV, Vasavada S, Raz S: Grading pelvic prolapse and pelvic floor relaxation using dynamic MRI. Urology 1999; 54:454–458
12. Yang A, Mostwin JL, Rosenshein NB, Zerhouni EA: Pelvic floor descent in women: dynamic evaluation with fast MR imaging and cinematic display. Radiology 1991; 179:25–33
13. Lienemann A, Anthuber C, Baron A, Reiser M: Diagnosing enterocele using dynamic magnetic resonance imaging. Dis Colon Rectum 2000; 43:205–213
14. Okamoto N, Maeda K, Kato R, Aoyama H, Hanai T, Sato H, Masumori K, Maruta M: Enterocele associated with rectocele revealed by dynamic pelvic CT. Abdom imageing 2005; 30: 679–681
15. Okamoto N, Maeda K, Kato R, Senga S, Sato H, Hosono R: Dynamic pelvic three dimension CT (D-3DCT) for investigation of pelvic abnormalities in patients with rectocele and rectal prolapse. J Gastroenterol 2006; 41: 802–806