

## ORIGINAL ARTICLE

# Total Management of Diabetic Foot Ulcerations – Kobe Classification as a New Classification of Diabetic Foot Wounds

Hiroto Terashi,<sup>1</sup> Ikuro Kitano<sup>2</sup> and Yoriko Tsuji<sup>2</sup>

<sup>1</sup>*Department of Plastic Surgery, Graduate School of Medicine, Kobe University, Kobe, Japan*

<sup>2</sup>*Wound Healing Center, Shin-Suma General Hospital, Kobe, Japan*

(Received for publication on September 13, 2010)

(Revised for publication on October 27, 2010)

(Accepted for publication on November 25, 2010)

Treatment must be conducted after proper assessment of diabetic foot wounds. This implies appropriate foot care and the use of proper footwear from the perspectives of prophylaxis and walking. Diabetic foot wounds have some wound impairment factors, including peripheral neuropathy (PN), peripheral arterial disease (PAD), and infection; such wounds comprise combinations of these lesions. An additional goal besides wound healing is gait salvage. Here, we propose a simple new four-level classification of diabetic foot ulcerations, which we have termed the Kobe classification, in order to assess the wounds more easily and treat them systematically; the classification is as follows: Type I, mainly PN; Type II, mainly PAD; Type III, mainly infection; Type IV, PN+PAD+infection. (Keio J Med 60 (1) : 17–21, March 2011)

**Keywords:** diabetic foot, peripheral neuropathy, peripheral arterial disease, infection

### Introduction

The incidence of diabetic foot disease is on the rise throughout the world.<sup>1</sup> Improving the management of diabetic foot disease is a mission for the plastic surgeon in Japan and other Asian countries because there are no specialist podiatrists in these countries. To promote the total management and proper treatment of this condition, a classification system for wounds of the diabetic foot is needed. Currently, there are three main classification systems worldwide. The first is the Wagner classification system, which is the most widely accepted and universally used grading system.<sup>2</sup> The second is the depth-ischemia classification,<sup>3</sup> a modification of the Wagner system. The third is the University of Texas wound classification system.<sup>4</sup> Because the Wagner classification system is basically anatomical, with gradations of superficial ulcer, deep ulcer, abscess osteitis, gangrene of the foot, and gangrene of the entire foot, it is not always suitable for assessing wound therapy. The depth-ischemia classification is complicated and it is difficult to

grade the wound appropriately. The University of Texas wound classification system assesses ulcer depth, the presence of wound infection, and the presence of clinical signs of lower extremity ischemia. This system uses a matrix with grade on the horizontal axis and stage on the vertical axis. It is more descriptive and shows a greater association with increased risk of amputation and prediction of ulcer healing than the Wagner system does;<sup>5</sup> however, in the University of Texas system, wounds are classified into 16 categories, and it is difficult to understand them and to deal them with.

Type 2 diabetes is a growing epidemic in Asia, characterized by rapid rates of increase over a short period and onset at a relatively young age and low body mass index.<sup>6</sup> Kadowaki, *et al.* reported that early insulin response was an independent predictor for diabetes.<sup>7</sup> In Japanese men with normal glucose tolerance, even a small increase in BMI produced a decrease in beta cell function disproportionate to that in insulin sensitivity,<sup>8</sup> indicating that there are inherent differences between Asian and Caucasian populations. Furthermore, Asia

Presented at the 1774th Meeting of The Keio Medical Society in Tokyo, July 10, 2010.

Reprint requests to: Hiroto Terashi, MD, PhD, Department of Plastic Surgery, Graduate School of Medicine, Kobe University, Kusunoki-cho 7-5-2, Chuo-ku, Kobe 650-0017, Japan, E-mail: terashi@med.kobe-u.ac.jp

Copyright © 2011 by The Keio Journal of Medicine

**Table 1** Kobe classification and treatment for each type of wound

Type	Pathophysiology	Main treatment
I	Mainly PN	Pressure relief
II	Mainly PAD	Revascularization
III	Mainly infection	Early debridement
IV	PN+PAD+infection	Revascularization and debridement on a case-by-case basis

does not have the distinct discipline of podiatric medicine, such as exists in Europe and America. The podiatrist is a special medical doctor who serves the most important role for mechanical and metabolic conditions affecting the foot. Therefore, we need to establish a new classification system, such as the Kobe classification, for diabetic foot wounds that is more appropriate for Asian people because of the differences between Asian and Caucasian populations.

### Materials, Methods, and Results

Three etiologies of diabetic foot wounds are considered: peripheral neuropathy (PN), peripheral arterial disease (PAD), and infection. The pathophysiological combination of this triad leads to many wounds.<sup>9</sup>

We treated and followed up 266 limbs with diabetic ulcers at Shin-Suma general hospital from November 2002 to August 2008. We propose a new simple classification of diabetic foot ulcerations, the Kobe classification, in order to assess wounds more easily and treat them systematically. The system classifies wounds into four types:

Type I, mainly composed of PN, 49 limbs

Type II, mainly composed of PAD, 180 limbs

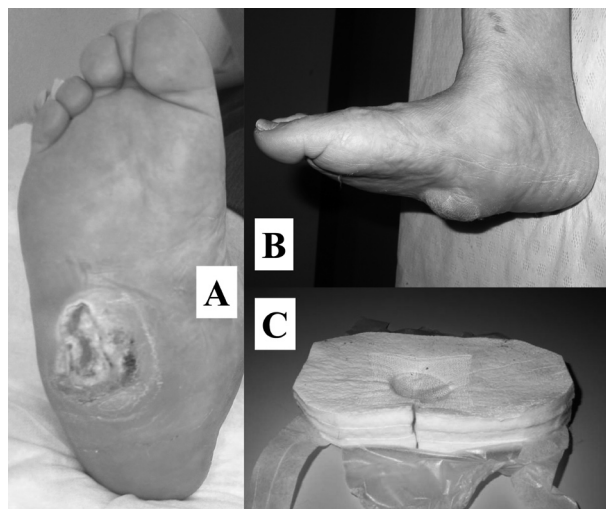
Type III, mainly composed of infection, 16 limbs

Type IV, all three combined (PN+PAD+infection), 21 limbs.

**Table 1** shows the new classification and the main treatment for each wound type.

#### Type I

Type 1 wounds mainly result from PN. There are three type of PN, i.e., autonomic neuropathy, motor neuropathy, and sensory neuropathy.<sup>10</sup> Autonomic neuropathy can result in the opening of arteriovenous shunts on the plantar surface of the foot. The shunts result in a redirection of blood flow away from the nutrient capillaries and the skin and can also cause the loss of sweating. Poor sweating can cause the foot to become dry and cracked. Recently, it was established that the sweat from eccrine glands in the undiseased state contains much epidermal growth factor (EGF) and that the epithelium of the eccrine ducts contains epidermal growth factor receptors



**Fig. 1** The patient is a 45-year-old woman who had had diabetes mellitus for 5 years.

(A) Ulceration beneath callus on the right sole due to Charcot foot.

(B) Lateral view.

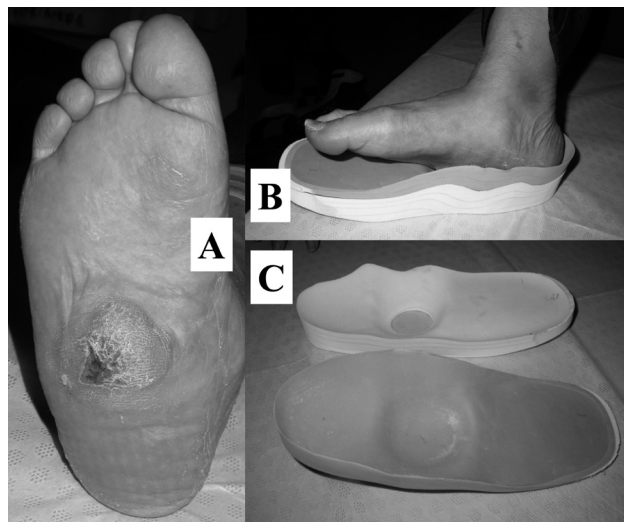
(C) Footwear for pressure relief.

(EGFR).<sup>11</sup> The reduced proliferation of keratinocytes from the eccrine ducts can result in downregulation of the re-epithelialization process in wound healing of partial-thickness ulcerations. Although the condition known as Charcot foot is poorly understood, one of the main steps in its pathogenesis is autonomic neuropathy with increased blood flow to the bone.<sup>12</sup> Motor neuropathy can lead to foot deformities from intrinsic muscle atrophy and imbalance of the muscles.<sup>10,13</sup> A common such deformity is the claw or hammer toe deformity. As this occurs, the fat pad is pulled off the metatarsal heads. This may lead to high pressure points under the metatarsal heads on walking. Furthermore, sensory neuropathy can disturb wound healing. Consequently, the mainstay of treatment for Type I wounds is pressure relief.

In a representative case, a 45-year-old woman who had had diabetes mellitus for five years was worried about ulceration beneath callus on her right sole due to Charcot foot (**Fig. 1**). The wound gradually healed over 2 months as a result of footwear prepared to achieve pressure relief, and the patient now wears her own prophylactic shoes with no recurrence (**Fig. 2**).

#### Type II

Type II wounds mainly result from PAD. Fontaine III and IV scores for chronic ischemia represent critical limb ischemia (CLI). Type II lesions are equivalent to Fontaine IV. The most important consideration for this type of lesion is to gain adequate blood flow to the wound with revascularization therapy. There are many assessment tools for circulation. Among them, we believe that the skin perfusion pressure (SPP) around the

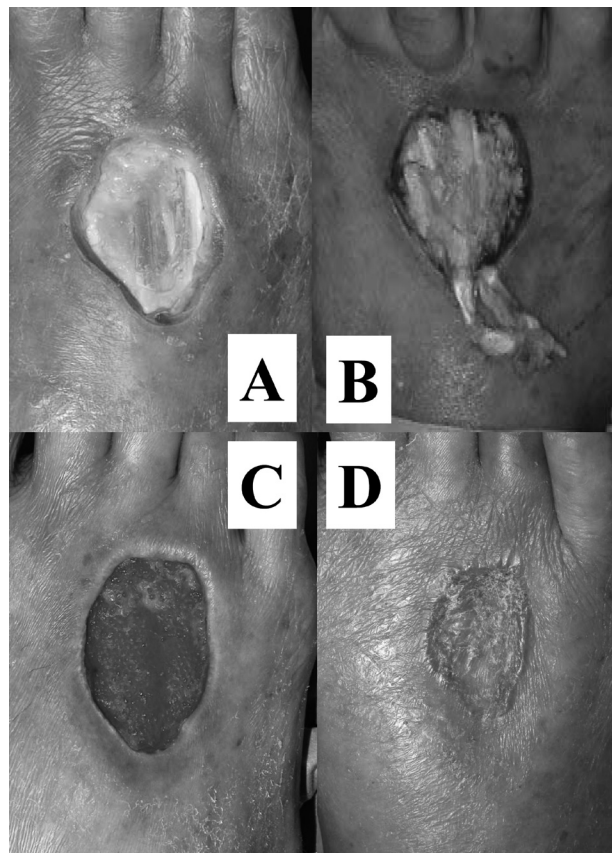


**Fig. 2** Same patient as in Fig. 1; Two months after the therapy. (A) The wound had healed. (B) Lateral view. (C) The patient's own prophylactic insole.

wound is the most important.<sup>14</sup> Especially in hemodialysis patients, SPP is the most useful tool for detecting PAD, and has superior sensitivity and specificity to others, including the ankle-brachial index (ABI), the toe brachial index (TBI), and the transcutaneous oxygen measurement (TcPO<sub>2</sub>).<sup>15</sup> We define the dynamic SPP-1 measure as the SPP when the anterior tibial artery (ATA) is occluded manually, and the dynamic SPP-2 measure as the SPP when the posterior tibial artery (PTA) is occluded manually.<sup>16</sup>

For good wound healing, we have to recognize the original angiosomes of the foot and find an alternative to the ischemic angiosome through arterial-arterial connection using the angiogram view and dynamic SPP data. Up to 15% of ischemic wounds cannot successfully heal despite revascularization.<sup>17</sup> This failure is considered due to inadequate revascularization of the wound and/or inadequate wound care. Revascularization of the directly supplying ischemic angiosome is more successful than revascularization of indirectly supplying angiosomes.<sup>18</sup> In the vascularly compromised foot, collateral flow may be keeping the ischemic angiosome vascularized to some extent, with the original vasculature changed. Therefore, the plastic surgeon must plan to debride the necrotic tissue and gangrene and to cover the defects with the main arterial flow kept intact and the collateral flow undisturbed. Understanding the vascular network facilitates the design of incisions that sustain blood flow for the surgical wound to heal well.<sup>19</sup>

A representative case is that of a 70-year-old man who had dry necrosis on his right dorsum foot for 2 months. He had diabetes mellitus and had undergone hemodialysis for 5 years. His anterior tibialis artery (ATA) and pos-



**Fig. 3** The patient is a 70-year-old man who had had diabetes mellitus and had undergone hemodialysis for 5 years.

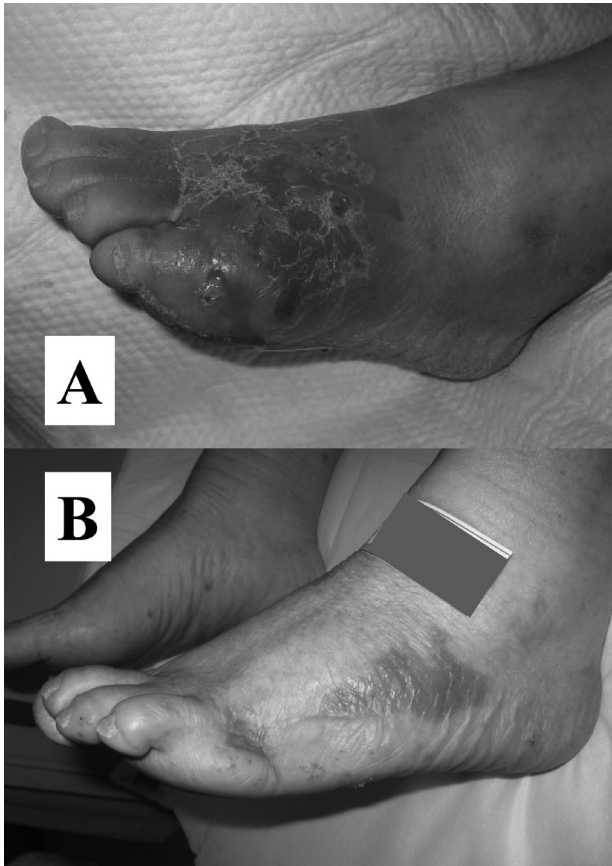
(A) Dry necrosis was present on the right dorsum foot for 2 months. (B) Debridement after revascularization. (C) Wound bed preparation after negative pressure wound therapy. (D) Six months after split-thickness skin grafting.

terior tibialis artery (PTA) were not palpable and the SPP value on the dorsum of the foot was 30mmHg. We diagnosed his right leg as having CLI. After revascularization with distal femoral-PTA bypass surgery, debridement and negative pressure wound therapy were carried out. Then, we grafted a split-thickness skin graft on the wound after wound bed preparation (**Fig. 3**).

### Type III

Type III lesions are mainly caused by infection. Infections of various types are common and are often severe in patients with diabetes mellitus. They indicate a serious acute problem requiring immediate surgical attention. Such wounds may be associated with long-term morbidity, including soft tissue infection, osteomyelitis, and the need for surgical resection. Consequently, it is important to assess the infectious wound accurately and to debride the necrotic devitalized soft tissues properly in good time for acute phase infectious wounds. These





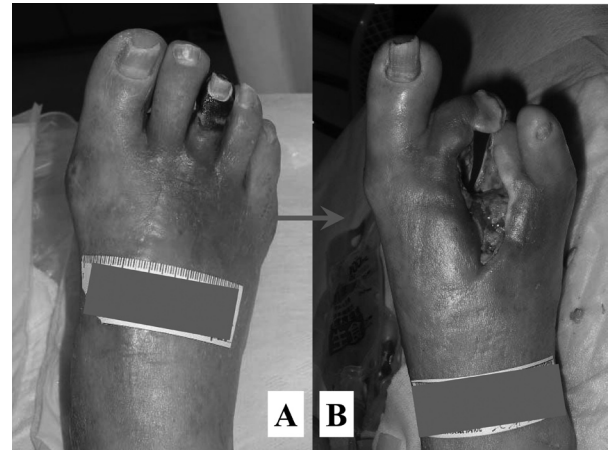**Fig. 4** The patient is a 60-year-old woman who had sudden-onset ulceration.  
(A) The wound generated much foul-smelling exudate.  
(B) Five years after an immediate debridement without any recurrence.

infections can easily spread to the proximal side along the tendons and fascia tissues. Early debridement and drainage is the most important consideration for the wounds of Type III.

A representative case involved a 60-year-old woman who had sudden onset ulceration with much foul-smelling exudate. The ATA and PTA were palpable. Laboratory data showed that CRP was 19.0mg/dl. Immediate debridement including resection of the fifth toe was carried out and conservative therapy was then followed. The wound had healed 1 month after the operation (**Fig. 4**).

#### **Type IV**

Type IV lesions are those caused by a combination of all three factors (PN+PAD+infection). There were originally three basic anatomic types of major foot infection in diabetes mellitus.<sup>20,21</sup> The first is infection from an ulcerated bunion/bunionette that may enter the medial/lateral plantar space. The second is from mal perforans ulcers after callus formation. The third is abscess occur-



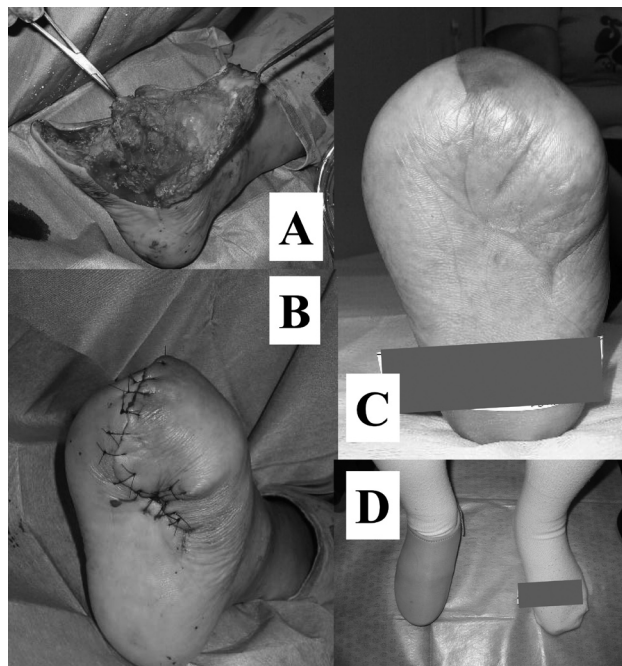
**Fig. 5** A 65-year-old woman had gangrene of her right third toe after an infection on the dorsum foot.  
(A) Critical colonization into her central plantar space was evident.  
(B) Wound bed preparation after endovascular therapy and immediate debridement.

ring chiefly in the central plantar spaces of the foot. Most of the third type are secondary infections of the early web space of the foot with patchy segmental arteriosclerotic occlusion of digital and metatarsal vessels on tinea pedis, followed by thrombosis of arteries adjacently.<sup>21</sup> Gangrene of the second, third, and/or fourth toes results. The mechanism is CLI from web space infection as a result of an occult PAD. It is very difficult to manage Type IV wounds properly. If SPP is low, early debridement could result in worsened necrosis. If the infection is out of sight or critical colonization exists, the revascularization procedure could make the wounds more infectious. When both procedures are needed, it is the most important which takes precedence and good timing is important. The decision must be made on a case-by-case basis.

A representative case is that of a 65-year-old woman who had gangrene of her third right toe after an infection on the dorsum foot. The infection subsided and critical colonization occurred in the central plantar space (**Fig. 5**). SPP data were 20mmHg on the dorsum and 25mmHg on the sole. First, revascularization therapy with an endovascular technique was done, followed by an immediate debridement before the expected infection could become established. After wound bed preparation with daily conservative therapy, SPP values of 60mmHg on the dorsum and 35mmHg on the sole were measured. A modified transmetatarsal amputation was done.<sup>19</sup> The patient has had no recurrence of ulceration and can walk easily with her custom-made footwear (**Fig. 6**).

#### **Discussion**

Treatment must be conducted after proper assessment



**Fig. 6** Same patient as in Fig. 5; a modified transmetatarsal amputation was done.

(A) During the operation.

(B) Just after the operation.

(C) One year after the operation.

(D) No recurrence of ulceration with custom-made footwear.

of diabetic foot wounds. This implies appropriate foot care and the use of proper footwear from the perspectives of prophylaxis and walking. Diabetic foot wounds have some wound impairment factors, including PN, PAD, and infection. These factors often occur in combination in such lesions. An additional goal besides wound healing is gait salvage.

The newly proposed Kobe classification system is simple and easy to understand. First, we will try to apply it in clinical practice and will modify it in the future if necessary. The Kobe classification system will hopefully provide a useful frame of reference when tackling difficult problems with respect to the assessment and the treatment of a wide variety of troublesome wounds on Asian diabetic feet.

## References

- Boulton AJM, Vileikyte L, Ragnarson-Tennvall G, Apelqvist J: The global burden of diabetic foot disease. *Lancet* 2005; **366**:1719–1724.
- Wagner FW: Supplement: algorithms of foot care. In: Levin ME, O'Neal LW, eds, *The Diabetic Foot*, St. Louis, Mosby, 1983; 291–302.
- Brodsky JW: The diabetic foot. In: Coughlin MJ, Mann RA, Saltzman CL, eds, *Surgery of the Foot and Ankle*, St. Louis, Mosby, 2007, 1281–1368.
- Armstrong DG, Lavery LA, Harkless LB: Validation of a diabetic wound classification system. The contribution of depth, infection and ischemia to risk of amputation. *Diabetes Care* 1998; **21**: 855–859.
- Oyibo SO, Nguyen HC, Jude EB, *et al*: A comparison of two diabetic foot ulcer classification systems. *Diabetes Care* 2001; **24**: 84–88.
- Chan JCN, Malik V, Jia W, *et al*: Diabetes in Asia: epidemiology, risk factors, and pathophysiology. *JAMA* 2009; **301**: 2129–2140.
- Kadowaki T, Miyake Y, Hagura R, *et al*: Risk factors for worsening to diabetes in subjects with impaired glucose tolerance. *Diabetologia* 1984; **26**: 44–49.
- Kuroe A, Fukushima M, Usami M, *et al*: Impaired beta-cell function and insulin sensitivity in Japanese subjects with normal glucose tolerance. *Diabetes Res Clin Pract* 2003; **59**: 71–77.
- Levin ME: Pathogenesis and general management of foot lesions in the diabetic patient. In: Bowker JH, Pfeifer MA, eds, *The Diabetic Foot*, St. Louis, Mosby, 2001, 219–260.
- Tanenbarg RJ, Schurer MP, Greene DA, Pfeifer MA: Neuropathic problems of the lower extremities in diabetic patients. In: Bowker JH, Pfeifer MA, eds, *The Diabetic Foot*, St. Louis, Mosby, 2001, 33–64.
- Saga K: Structure and function of human sweat glands studied with histochemistry and cytochemistry. *Prog Histochem Cytochem* 2002; **37**: 323–386.
- Sanders L and Frykberg RG: Charcot neuroarthropathy of the foot. In: Bowker JH, Pfeifer MA, eds, *The Diabetic Foot*, St. Louis, Mosby, 2001, 439–466.
- Bus SA, Maas M, Cavanagh PR, *et al*: Plantar fat-pad displacement in neuropathic diabetic patients with toe deformity: a magnetic resonance imaging study. *Diabetes Care* 2004; **27**: 2376–2381.
- Tsuji Y, Terashi H, Kitano I, Tahara S: Importance of skin perfusion pressure (SPP) in the treatment of critical limb ischemia (CLI). *Wounds* 2008; **20**: 95–100.
- Okamoto K, Oka M, Maesato K, *et al*: Peripheral arterial occlusive disease is more prevalent in patients with hemodialysis: comparison with the findings of multidetector-row computed tomography. *Am J Kidney Dis* 2006; **48**: 269–276.
- Terashi H, Iwayama T, Iida O, *et al*: Dynamic SPP – a new measure of assessment for wound healing capacity and alternative angiome in critical limb ischemia (CLI). *Plast Reconstr Surg* 2010; **126**: 215e–218e.
- Attinger CE, Evans KK, Bulan E, *et al*: Angiosomes of the foot and ankle and clinical implications for limb salvage: reconstruction, incision, and revascularization. *Plast Reconstr Surg* 2006; **117**(Suppl): 261S–293S.
- Iida O, Nanto S, Uematsu M, *et al*: Importance of angiosome concept in endovascular therapy for patients with critical limb ischemia. *Catheter Cardiovasc Interv* 2010; **75**: 830–836.
- Terashi H, Kitano I, Tsuji Y, *et al*: A modified transmetatarsal amputation. *J Foot Ankle Surg* 2011; in press.
- Meade JW, Mueller CB: Major infections of the foot. *Med Times* 1968; **96**: 154–165.
- O'Neal LW: Surgical pathology of the foot and clinicopathologic correlations. In: Levin ME, O'Neal LW, eds, *The Diabetic Foot*, St. Louis, Mosby, 1983; 483–512.